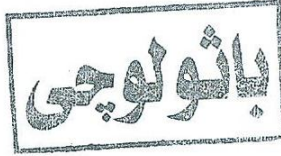




كلية الطب
Faculty of Medicine

الثالثة
درجة اولى
2015



جامعة الفيوم
Fayoum University

FINAL PATHOLOGY EXAM (1)

25 May 2015

Time: 2 hours

Marks: 75

Answer All The Following Questions:

1- Problem Solving:

(5 marks)

An old male patient, 55 years, with history of long history of mitral valve stenosis, following repeated tonsillitis in young age. Now, following tooth extraction, he developed heart arrhythmias and sudden blindness.

- What is your provisional diagnosis.
- What are the pathological features of the mitral valve.
- What are the possible associated embolic & toxic lesions.

2- Give Short Account on:

(15 marks)

- Causes of Lung abscesses.
- Causes of Acute Organic Intestinal Obstruction
- Causes of True Aneurysms.

3- Describe the Pathological Features of:

(15 marks)

- Lung in Bronchiectasis
- Colon in Ulcerative Colitis.
- Stomach in Peptic Ulcers.

4- Enumerate the Complications of:

(15 marks)

- Typhoid fever
- Liver Cirrhosis.
- Atherosclerosis in large and small arteries.



5- Define:

(10 marks)

- a- Pneumothorax
- b- Varicose veins.
- c- Aschoff body.
- d- Bronchial Carcinoid
- e- Meckel s diverticulum.

6- Complete:

(10 marks)

- a- Two types of non neoplastic colonic polyps
- b- Two examples of Tongue ulcers.
- c- Two causes of Acute Laryngitis.
- d- Two causes of Secondary Hypertension.
- e- Two examples of Primary Malignant Hepatic Tumors.

7- Choose The Correct Answer:

(5 marks)

- a- The followings are complications of Rheumatic fever except
 - 1- Subacute Bacterial Endocarditis
 - 2- Fleeting polyarthritits
 - 3- Acute bacterial endocarditis
 - 4- Aortic athrosclerosis
- b- The sigmoid colon is a common site of the followings except:
 - 1- Ulcerative colitis
 - 2- Intestinal Tuberculosis
 - 3- Ulcerative malignancy
 - 4- Intestinal Bilharziasis
- c- The following are common Causes Gall Stones except:
 - 1- Hypercholesterolimia
 - 2- Hyperuricemia
 - 3- Hemolytic anemia
 - 4- Bile stasis
- d- Malignant tumor of the Pleura covering the lung is called:
 - 1- Bronchial Carcinoid
 - 2- Bronchogenic carcinoma
 - 3- Mesothelioma
 - 4- Malignant Teratoma
- e- One of the following is not a common cause for Chronic Hepatitis:
 - 1- Hepatitis A infection
 - 2- Hepatitis B infection
 - 3- Hepatitis C infection
 - 4- Auto-Immune hepatitis